

Case Series

Combination of Laser Acupuncture and Low Level Laser Therapy for Treatment of Non-healing and Infected Wounds

Uwe Petermann DVM

ABSTRACT

Pulse-controlled laser acupuncture involves the combination of laser acupuncture (LA) with low level laser therapy (LLLT). These are effective individual therapies, but when used together, there is a synergy which provides clinically effective therapy for many types of non-healing traumatic or surgical wounds. The author has successfully used laser therapy for the past 25 years to treat several hundred cases of non-healing and/or infected wounds, including wound infections populated by organisms resistant to multiple antibiotics. This paper describes the successful treatment of large non-healing wounds using laser acupuncture and low level laser therapy without additional surgical or medical interventions.

Key words: Laser acupuncture, low level laser therapy, wound healing, wound infection, MRSA

	ABBREVIATIONS
TCM	Traditional Chinese medicine
LA	Laser acupuncture
LLLT	Low level laser therapy
MRSA	Methicillin-resistant Staphylococcus aureus
ATP	Adenosine triphosphate

Acupoints are small areas of reduced electrical resistance within the fascia and muscles near the surface of the body consisting of a high concentration of free nerve endings and blood vessels.^{1,2} Acupuncture stimulates nerves to evoke autonomic reflexes and neurohumeral changes via higher brain centers to restore homeostasis of the body.^{1,2} The acupoints effective for specific disorders have been determined by thousands of years of experience in Traditional Chinese Medicine (TCM).³ Acupoints can be stimulated by dry needles, electricity or laser. Laser acupuncture (LA) is a relatively new technique compared to other forms of acupoint stimulation. Its advantage over dry needle acupuncture is that it is generally painless and there is no need to touch the skin.⁴

Laser photon absorption is thought to stimulate nerve endings at acupoints and induce therapeutic effects via autonomic nervous system reflexes and higher brain centers, similar to other forms of acupoint stimulation.⁵ The laser light appears to hyperpolarize local nerve endings and reduce muscle spasms and pain. Laser photons can be directly absorbed into cells by means of a so-called “antenna pigment” which is

the flavoprotein-metal-redox system, an important link within the mitochondrial respiratory pathways to generate adenosine triphosphate (ATP). Increased ATP production is the primary mechanism of action of both LA and LLLT. Absorbed laser photons are transformed directly into cellular energy.⁴⁻⁸ Diseased and damaged tissues require high levels of energy to absorb inflammatory secretions and other debris, synthesize new structures, rebuild damaged tissue and return to normal function. Application of LLLT to areas of damaged tissue is thought to contribute to the rebuilding and healing process by increasing energy production within the diseased cells.⁹

Low level impulse laser light can be applied focally over acupoints at very specific wavelengths, pulse power, duration and frequencies to perform LA.⁴ The resonance frequency of the laser and the wavelength of the laser light are very important and have to be selected carefully. Impulse laser devices emit a high intensity, short duration, pulsing light with a wavelength of 904 nanometers (nm), a peak pulse power of up to 90 watts (W) and pulse duration of 200 nanoseconds (ns). Tissue penetration of these impulse lasers is up to 15 centimeters (cm) due to their powerful light pulses. Due to their ultra-short duration, no thermal or coagulating effects occur in the tissue, even at high impulse frequencies of 40,000 hertz (Hz). Treatment of acupoints requires a treatment duration of 15-30 seconds while topical treatment of wounds (low level laser therapy, LLLT) generally requires about 30-60 seconds per square centimeter of surface, depending on the depth of the wound.

LA has been successfully used to treat immune-

mediated disorders and for stimulation of the immune system in general.^{7, 9-11} Laser light has also been applied topically to wounds in order to reduce inflammation, increase blood perfusion, enhance clearance of peroxide radicals, promote collagen growth, delineate damaged tissue and promote wound healing. In addition, it has shown remarkable effects in its ability to improve blood perfusion in micro-circulatory disorders.^{7, 9-11}

A French acupuncturist, Dr. Paul Nogier, developed the use of low-level laser therapy for acupuncture on humans and described a range of laser frequencies (Table 1) that proved particularly effective for acupoint stimulation and other clinical applications. In continuous wave lasers, these frequencies modulate the power as a sinus wave versus impulse lasers which emit very short flashes of laser light and have their frequency described in units of pulses per second. These frequencies are characterized by special resonances with specific tissues, tissue conditions and acupoints that vary based on location. Nogier's laser frequency A (Nfr-A) is particularly useful for treating wounds, inflammation and irritable foci in the body and

teeth. Laser frequency Nfr-B has a special affinity for ligaments, tendons and all organ acupoints (e.g. KID-7 which is identical with the auricular Kidney point, LIV8 which is identical with the auricular Liver point, LU-7 which is identical with the auricular Lung point). Laser frequency Nfr-C is useful to treat disorders of joints and bones and to treat all body acupoints. Laser frequency Nfr-E is useful to stimulate nervous tissue function and is especially good for spinal cord disorders.¹²

CASE STUDIES

All horses and dogs included in this case series were patients of the author's veterinary clinic in Melle, Germany (Table 2). They were presented to the author for LLLT after unsuccessful treatment at other veterinary clinics. Euthanasia had been recommended for several animals due to extremely severe wounds that were considered untreatable by conventional medical standards. The Physiolaser Olympic 90 W/904 nm^a and the Laser pen 40 W/904nm^b were the LLLT units used by the author in this study (Figures 1A and 1B). A 90 W impulse laser

Table 1: Nogier frequencies used for low-level laser therapy and laser acupuncture with clinical applications

Frequency	A	B	C	E
Hz	292	584	1,168	4,672
Indications	Wounds, inflammation, irritable foci in body and teeth	Tendonitis, arthritis, fractures, organ acupoints	Tendonitis, arthritis, fractures, all body acupoints except feet	Nerve and spinal cord diseases

Table 2: Signalment for 9 cases with non-healing traumatic or surgical wounds.

Case	Breed	Species	Age	Sex	Wound Chronicity	TM No	TM Type	TM Success	LLLT TM Owner	Total TM Time
1	Hanoverian	Equine	7 Mo	M/C	2 Wks	15	LA LLLT	Yes	3 mo	4 Mo
2	German Shephard	Canine	3 Yr	M	4 Mo	6	LA LLLT	Yes	3 wks	4 Wks
3	Mixed Breed	Canine	5 Yr	M	1 Yr	6	LA LLLT	Yes	3 wks	3 Mo
4	Crossbred	Equine	2 Yr	M	6 Mo	20	LA LLLT	Yes	None	2 Mo
5	Crossbred	Equine	6 Yr	M/C	7 Wks	14	LA LLLT	Yes	6 wks	2 Mo
6	Warmblood	Equine	3 Yr	M/C	3 Mo	7	LA LLLT	Yes	None	3 Wks
7	Hanoverian	Equine	2 Yr	M/C	6 Wks	24	LA LLLT	Yes	None	4 Mo
8	Trakehnen	Equine	18 Yr	F	3days	40	LA LLLT	Yes	6 wks	4 Mo
9	Scottish Terrier	Canine	6 Yr	M	1 Wk	4	LA LLLT	Yes	None	12 Days

TM = treatment; No = number; Mo = month(s); Wk/Wks = week(s); Yr = year

M = male; F = female; M/C = castrated male

LA = Laser Acupuncture; LLLT = Low Level Laser Therapy

single probe and a 40 W impulse laser pen were used for acupoint stimulation and the tip of the laser device was placed directly on each acupoint for 20 seconds. Two 90 W impulse single probes and a 5x30 W impulse laser cluster probe was used for topical treatment of wounds. The probe was held as close as possible to the wound without directly touching, to avoid contaminating the laser tip or the wound. Topical LLLT took 2-5 minutes of treatment for each location (Figure 2). Acupuncture points were used for stimulation of the immune system (SP-4, TH-5) and to improve blood perfusion (LU-9). The Tendino-muscular Meridian or Sinew Channel associated with the wound location was treated at its Ting Tonification and specific Reunion Points.

At the initial session for each animal, the total time for diagnosis and treatment was usually 40 minutes with subsequent sessions lasting 20-30 minutes. Between treatment sessions, the wounds were bandaged with wet dressings of mild Rivanol® (2g/L)^c and Arnica tincture (10ml/L)^d. The bandage was renewed after each treatment. The frequency and overall number of treatments varied according to the individual needs of the patient. Initially, laser treatments were repeated daily until the wound showed a healthy bed of granulation tissue; then treatment frequency was reduced to 2-3 times a week. For some patients, after comprehensive instruction, the caretaker continued daily treatment at home using a 90 W impulse laser.

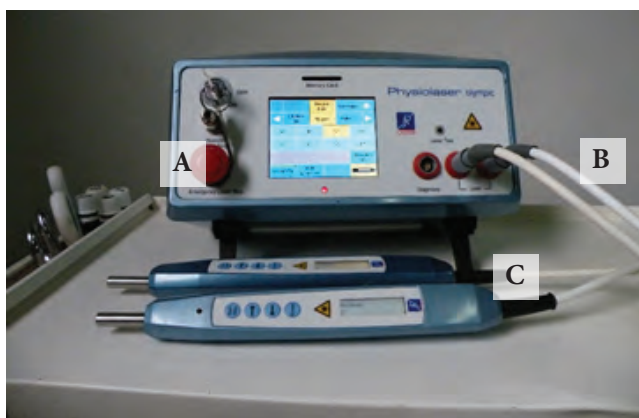


Figure 1: Physiolaser Olympic low level impulse laser unit (A) connected by cable (B) with 2x 90 watt single probes for acupoint stimulation and topical therapy (C).



Figure 2: Laser Pen 40 W/904nm for acupoint stimulation in charging station.

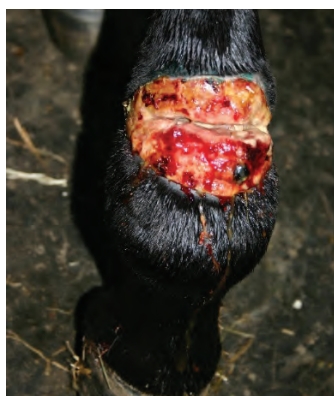

Figure 3A



Figure 3B

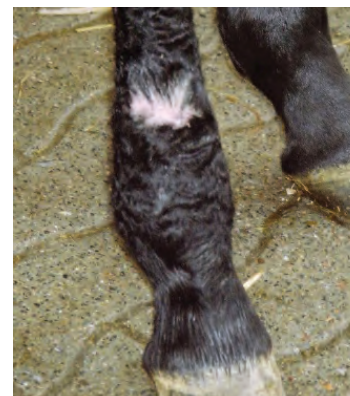


Figure 3C

Figure 3 (Case 1): Seven Month Old Foal with Chronic Non-Healing Wound of the Right Front Fetlock

Figure 3A: Initial presentation with a 10 cm non-healing wound composed of exuberant granulation tissue located on the anterior surface of the proximal right front fetlock

Figure 3B: This photograph shows the right fetlock illustrated in Figure 3A after 3 weeks of laser acupuncture. The wound has a healthy bed of granulation tissue which is bordered by 5mm of normal epithelia.

Figure 3C: This photograph shows the right fetlock lesion demonstrated in figure 3A after 4 months of laser therapy without any adjunctive treatment. The enlarged fetlock and extensive area of exuberant granulation tissue has been replaced by a normal sized fetlock and small scar on the anterior surface of the leg.

Case 1

A 7-month-old pasture-maintained foal was presented with a neglected 10 cm wound located on the anterior surface of the proximal right front fetlock. Diffuse edematous swelling of the joint was present with a circumference of 50 cm. When the wound was initially discovered, standard treatments including bandages and antibiotics were administered for 2 weeks without success before the animal was presented for laser acupuncture. LA therapy included daily treatment for the first 5 days and 3 times a week, thereafter, with four 90 W impulse single probes for 15 minutes, together with LA at SP-2 to support wound healing and at TH-5 and SP-4 to stimulate the immune system (Table 3). Between treatment sessions, the wound was covered using wet Entozon®/Arnica bandages. No adjunctive treatments such as antibiotics were administered. Three weeks after treatment started, the swelling was reduced by 50%. The wound had contracted and displayed normal epithelialization along a bed of healthy granulation tissue. The foal was then treated on a daily basis by the caretaker for the next 3 months, with

maintenance laser treatments once every other week. After 4 months of treatment in total, healing was complete.

Case 2

A 3-year-old male German Shepherd mix was presented for LLT and LA with a 12 cm linear wound in the dorsal right shoulder area parallel to the vertebral spinous processes. Bacterial culture with antibiotic sensitivity had verified a Methicillin-resistant *Staphylococcus aureus* (MRSA) infection. The wound had been treated unsuccessfully for four months in a small animal hospital and euthanasia was recommended. When the dog was presented for treatment, the wound was characterized by a highly destructive, infiltrative infection. The granulation tissue contained multiple fistulous tracts with marked secretory activity (Figure 4A). When treatment commenced, antibiotics and anti-inflammatory drugs were discontinued. In addition to LLLT of the wound with frequency A'' for 10 minutes, LA was performed at the immune-stimulating points TH-5 and SP-4. During the first session, the superficial surface of the wound displayed

Table 3: Acupoints used in the case studies- indications and treatment time with impulse laser strength, wavelength and frequencies.

Acupoints	TCVM indication	PCLAC indication	Laser Strength (Watt)	Laser wavelength (nm)	Pulse Frequency (Herz)	Treatment time (seconds)
PC-9	Ting point PC	Ting point	90	904	Rf. PC 530	20
LU-9	Tonifying point LU	Blood perfusion	90	904	Rf. LU 824	20
LIV-1	Ting point LIV	Ting point LIV	90	904	Rf. LIV 442	20
LIV-8	Tonifying point LIV	Tonifying point LIV	90	904	Rf. LIV 442	20
TH-5	Luo- TH and opening point	Luo point TH	90	904	Rf. TH 732	20
BL-23	Back shu point KID, Yang aspect KID	Back shu point Sympathetic aspect KID	90	904	Nogier freq. C 1168	20
SP-2	Tonifying point SP	Anabolic masterpoint	90	904	Rf. SP 702	20
SP-4	Luo- SP and opening point	Luo point SP	90	904	Rf. SP 702	20
GB-23	Reunion point TMM	Reunion point TMM	90	904	Rf. GB 583	20
GB-43	Tonifying point GB	Tonifying point GB	90	904	Rf. GB 583	20
GB-44	Ting point GB	Ting point GB	90	904	Rf. GB 583	20
SI-18	Reunion point TMM	Reunion point TMM	90	904	Rf. GB 791	20

nm=nanometers, hertz = cycles per second; Nogier- frequency= Nf., Reininger- (meridian-) frequency= Rf., TMM = tendino-muscular- meridian (or sinew channel)

marked secretory activity accompanied by a reduction in pain. After 10 days (5 treatments), there was significant wound contraction (a decrease to 9 cm) with resolution of wound drainage. The production of a healthy bed of granulation tissue accompanied by a normal surface epithelization was noted (Figure 4B). One month after the start of LLLT and LA therapy, the wound had healed without the aid of any additional surgery or antibiotic therapy (Figure 4C).

Case 3

A transverse femoral shaft fracture near the femoral head in a 5-year-old male mixed breed dog was repaired using a metal plate. Subsequent to fracture healing, the limb of the dog was paralysed with loss of reflexes and pain response. In an attempt to improve the function of the leg, the plate was removed during the second surgery, but the dog's condition remained unchanged. One year later, the dog was presented for acupuncture treatment with diffuse muscle atrophy of the leg with absent neurological reflexes and pain response. The surgical wound appeared closed but it was suspected there had been a problem with wound healing that had resulted in granuloma formation or infection within the scar tissue. The wound was treated topically with frequency A" for 2 minutes along with acupoints SP-2, SP-4 and TH-5. This was the only treatment the dog received. When the dog presented for

follow-up treatment 2 days later, the wound had opened and there was active surface drainage (Figure 5). Over the next 2 days, the initial surgical site became increasingly swollen and fluctuant. A large abscess developed and 2 days later, the abscess opened and 150 ml of purulent exudate drained from the site. Acupuncture treatment for the paralysis was then started. The Back *Shu* Association points from Kidney to Large Intestine along with the spinal cord in the lumbar area were treated with frequency E according to Nogier. This treatment (using a 90 W impulse laser) was then carried out at home by the caretaker for an additional month on a daily basis. On presentation for re-evaluation after 1 month of homecare, the dog was able to bear weight on the affected leg and had some degree of mobility. All neurological reflexes were now present and skin sensitivity had returned. Due to the improvement in the dog's condition, treatment was discontinued. At re-evaluation 2 months later, the dog could walk and run normally and the leg had developed normal musculature. Total recovery of the dog from non-healing wound and limb paralysis to wound resolution with normal limb mobility was 3 months.

Case 4

A bone chip in the hock of a 2-year-old crossbred stallion was removed by arthroscopic surgery. Post-surgically, an infectious tarsitis developed. Treatment

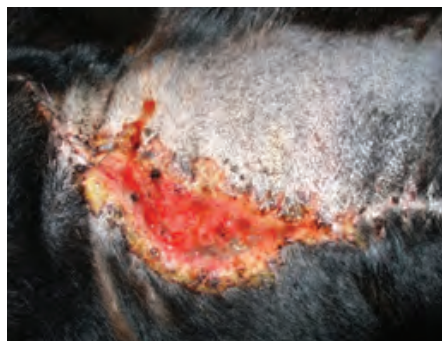


Figure 4A

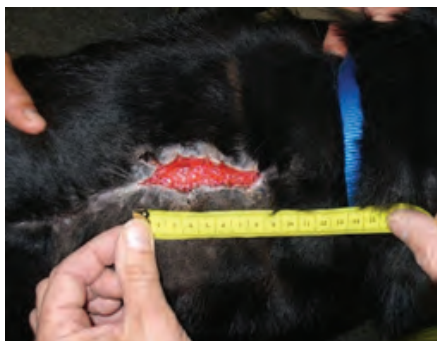

Figure 4B

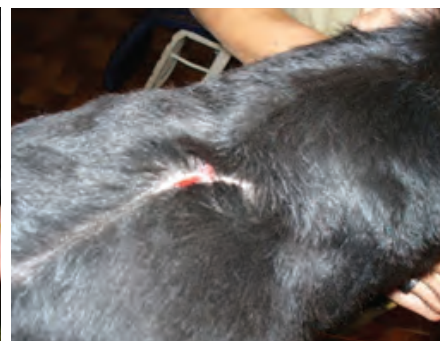

Figure 4C

Figure 4 (Case 2): A 3-year-old German Shepard mix presented with a 12 cm linear wound in the right shoulder area parallel to the vertebral spinous processes with culture positive MRSA infection.

Figure 4A: Initial presentation for laser acupuncture with a 12 cm linear wound located parallel to the dorsal spinous processes over the right shoulder.

Figure 4B: This photograph shows the dorsal right shoulder presented for treatment in Figure 4A after 10 days (5 treatments) of laser acupuncture. There is significant wound contraction (9 cm) and production of a healthy bed of granulation tissue bordered by a small edge of normal epithelia.

Figure 4C: This photograph shows the infiltrative inflammatory skin lesion presented in Figure 4A after 1 month of laser therapy. The skin is healed without the aid of further surgery or antibiotics.

(Reprinted with permission from: Petermann U. Kontrollierte Laserakupunktur bei Hund und Pferd. Sonntag Verlag in MVS Medizinverlag. Stuttgart, Germany: Thieme Verlagsgruppe 2011)

was first performed by the clinic where the surgery had taken place. Subsequent treatments followed at 3 other clinics, without success. When the horse was presented for laser treatment 6 months later, the infectious tarsitis had progressed to such severity that the horse was non-weight bearing on the affected limb and moved only with great difficulty on 3 legs. The circumference of the affected hock joint was 61 cm (Figure 6A). LLLT of the joint was performed using a 5 x 30 W multicluster 904 nm impulse laser and was applied dorsally, medially and laterally for 5 minutes on each surface. This technique was performed on a daily basis for one week. The following acupoints for the Sinew Channel of the Gallbladder and Liver were stimulated using the laser to control infection: GB-44, GB-43, LIV-1, LIV-8, SI-18 and CV-3. TH-5 and SP-4 were also treated to stimulate the immune system. After 14 days and 7 similar treatments, the circumference of the joint was reduced to 47 cm (Figure 6B). The horse now walked without lameness and could be lightly exercised at a trot for 5 minutes. After the third day of exercise,

following a sharp increase in the horse's training routine, joint inflammation and swelling reoccurred, accompanied by a spike in body temperature of 41°C (105.8°F). No antibiotics or other medications were administered and LLLT continued. A month later, after 12 more treatments, the patient went home. Over the following 3 months, the horse gradually began training to full capacity and was later sold after passing a veterinary examination without further issues.

Case 5

During surgery on the palmar annular ligament of the left hind fetlock of a 6-year-old crossbred gelding, routine arthroscopy of the digital synovial sheath was performed. Subsequent to the arthroscopy, a continuous discharge of synovial fluid occurred. Despite intensive therapy by the clinic performing the surgery, infection of the tendon sheath and necrotizing inflammation of the surgical site developed. After 6 weeks of unsuccessful treatment, the clinic's prognosis was grave and euthanasia

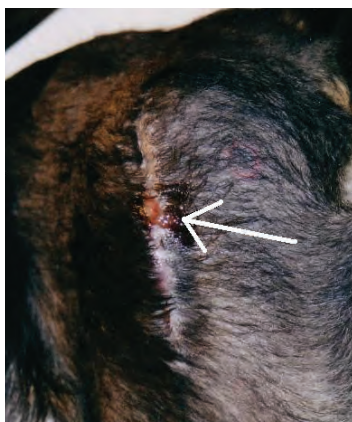

Figure 5 (Case 3): Five year old mixed-breed dog with a poorly healing surgical site present for 1 year after femoral fracture repair. The scar which had been closed for one year, opens and drains after the first laser acupuncture treatment (arrow).

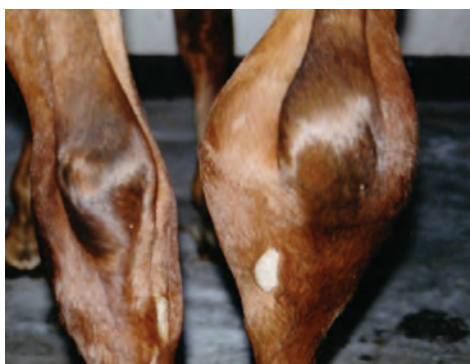

Figure 6A

Figure 6 (Case 4): Two year old crossbred stallion presented with an infected right tarsal joint of 6 month duration.

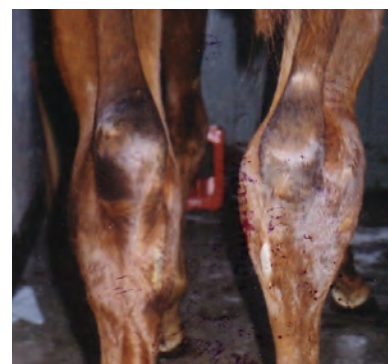

Figure 6B

Figure 6A: Initial presentation with a swollen right tarsal joint of 6 months and hock circumference of 61cm.

Figure 6B: This photograph shows the infected right tarsal joint presented in Figure 6A after seven LLLT treatments over a 14 day period. The circumference of the hock has reduced to 47cm and light exercise has started. (Reprinted with permission from: Petermann U. Kontrollierte Laserakupunktur bei Hund und Pferd. Sonntag Verlag in MVS Medizinverlag. Stuttgart, Germany: Thieme Verlagsgruppe 2011)

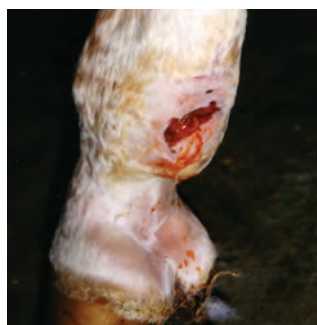

Figure 7A

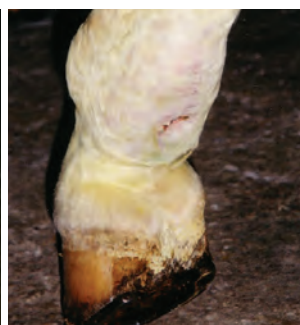

Figure 7B

Figure 7 (Case 5): A 6-year-old crossbred gelding presented with continuously discharging synovial fluid secondary to routine arthroscopy following palmar annular ligament surgery.

Figure 7A: Presentation of 6 x 2cm fetlock wound with escaping synovial fluid and a necrotic center.

Figure 7B: This photograph shows the fetlock wound illustrated in Figure 7A after 10 days of laser acupuncture with almost complete closure of the former surgery site.

recommended. The owner instead decided to try LLLT and LA. On examination, there was a 6 x 2 cm ulcer with a necrotic center located on the palmar surface of the fetlock that was draining synovial fluid. The horse was non-weight bearing, with only toe-touching due to severe pain and adhesions of the tendon sheath. The circumference of the fetlock joint was 49 cm (Figure 7A). LLLT of the infected tendon sheath was performed daily for 5 minutes using a 5 x 30 W multicluster 904 nm impulse laser. The following acupoints for the sinew channel of the Gallbladder were treated: GB-44, GB-43 along with the Reunion Points SI-18. TH-5 and SP-4 were also treated to stimulate the immune system. On the third day of treatment, no further secretion could be detected from the tendon sheath and the central necrotic area was considerably reduced to 5x1 cm in size. After 5 days of treatment, the wound no longer seeped synovial fluid and had shrunk to half its original size. After 10 days, the wound had almost completely closed (Figure 7B) and only a slight lameness was still noticeable. After a total of 14 days of treatment, the patient was released and received similar daily laser acupuncture treatments at home for another 5 weeks. Training was gradually increased to break down remaining adhesions, at which time the wound was completely healed and the horse was no longer lame. Six months later, he passed a veterinary examination and was sold to another owner.

Case 6

A 3-year-old gelding developed a post-operative fistula of the funiculus testis accompanied by firm swelling of the scrotum (25 cm diameter) and stiffness of the hind limbs. After 3 months of therapy with several antibiotics at 2 different clinics and a second operation, the fistula was still present and the gelding had lost 30% of his body weight. At this point laser therapy was recommended. The gelding received 7 treatments at intervals of 3-4 days, using a 90 W 904 nm impulse laser. The laser was applied over the infected funiculus for 5 minutes using frequency A". Laser acupuncture was performed at BL-23, KID-3, SP-5 (affects the funiculus testis) along with TH-5 and SP-4 to stimulate the immune system and improve wound healing. Complete resolution of the fistula and scrotal swelling along with normal hind leg mobility occurred after 21 days of therapy.

Case 7

A 2-year-old gelding developed a 10 x 8 cm area of ulceration on the flexor surface of the hock. Six weeks of conventional treatment included local and parenteral antibiotics, wet and dry bandages, stall rest, and several operations to remove proud flesh. Despite these interventions, the wound developed exuberant granulation tissue again (Figure 8A). The clinic gave a very poor prognosis for return to normal athletic performance and recommended euthanasia. At this point the owner

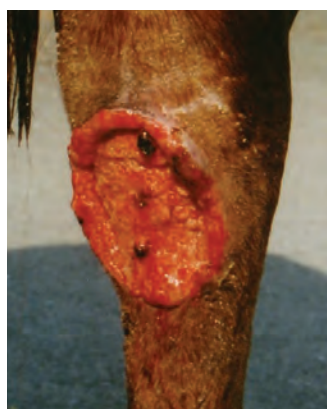

Figure 8A

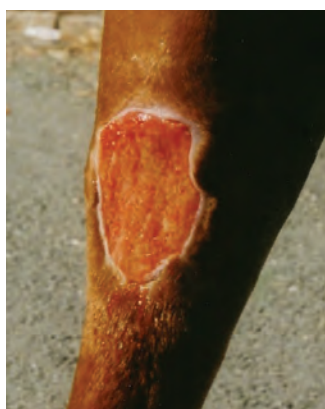

Figure 8B

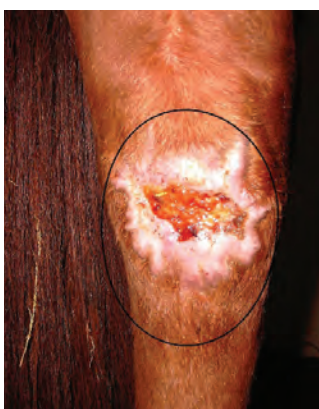

Figure 8C



Figure 8D

Figure 8 (Case 7): A 2-year-old gelding presenting with a 10 x 8 cm area of ulceration on the flexor surface of the hock unresponsive to 6 weeks of conventional treatment.

Figure 8A: Initial presentation of the gelding with a chronic 10 x 8 cm area of ulceration on the flexor surface of the hock.

Figure 8B: Photograph of the wound presented in 8A after 1 week of daily LLLT and LA treatment. There was marked improvement of the wound surface with formation of healthy granulation tissue bordered by 3-4 mm of new epithelia.

Figure 8C: Photograph of the wound presented in 8A with almost complete wound closure after 1 more week of daily therapy followed by weekly LLLT and LA for 2 additional months.

Figure 8D: Photograph of the wound after an additional 2 months of treatment every other week to address chronic surface epidual rupture associated with joint movement. The wound was successfully closed without further incident.

requested that the horse be evaluated for laser treatment by the author. Treatment consisted of surgical removal of the exuberant granulation tissue again followed by topical LLLT and LA daily for 2 weeks using a 90 W, 904 nm impulse laser at frequency A". The local area of skin loss was treated, together with acupoints SP-2 and TH-5 to promote wound healing. Between laser treatments, the wound was covered by a moist bandage with copper sulphate solution (5g/L) and tincture of Calendula, Echinacea and Arnica (each 10ml/L). After 1 week of treatment, there was improvement of the wound surface, with healthy granulation tissue and normal epithelization (Figure 8B). After the second week, treatment frequency was decreased to once weekly for 2 more months; at which point there was almost complete wound closure. (Figure 8C). One remaining problem was joint movement, which repeatedly ruptured the epidural surface; preventing complete wound closure. After an additional 2 months of treatment every other week, the wound was successfully closed without further incident (Figure 8D). The total time for complete resolution of this poorly healing wound on the surface of the hock was 4 months.

Case 8

An 18-year-old Trakehner breed mare sustained a ruptured superficial flexor tendon. There was a gap of 10 cm

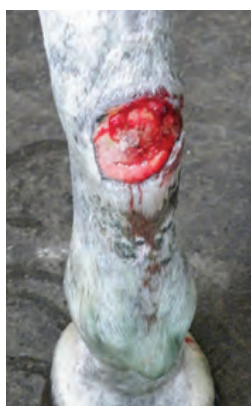

Figure 9A

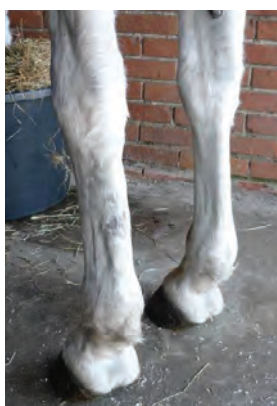

Figure 9B

Figure 9 (Case 8): An 18-year-old Trakehner mare with a ruptured superficial flexor tendon. There is a 10 cm gap between the two ends of the tendon and a poorly healing wound surface.

Figure 9A At presentation (3 days after the injury), there is a completely ruptured superficial flexor tendon of the left front leg with a 10 cm wound containing proud flesh.

Figure 9B: This photograph shows the ruptured tendon and poorly healing wound present in Figure 9A after 14 weeks of laser acupuncture. The wound has completely resolved and the tendon has healed without any other treatment.

between the two ends of the tendon. Surgical intervention was contraindicated due to the presence of deep infection. LLLT started 3 days after the accident and was performed over the area of the rupture every 2-3 days for 2 months using a 5x 30 W 904 nm impulse laser (Figure 9A) for about 5 minutes. In addition, there was laser stimulation of SP-2 (for wound healing and tissue repair), SP-4 and TH-5 (to stimulate the immune system), and PC-9 and GB-22 (the Sinew Channel/Tendino-muscular Meridian of the Pericardium). With the exception of tetanus vaccination, no other therapies were administered. On re-examination 2 months later, the wound had closed and the tendon was gradually healing. Treatment was continued at home for a further 6 weeks using a 90 W impulse laser, in order to encourage normal alignment of the healing tendon fibers. At the end of this period, the tendon had regained most of its original physiological structure and the mare was gradually returned to regular work (Figure 9B).

Case 9

A 6-year-old male Scottish Terrier was bitten by a male Doberman. This resulted in laceration of the skin over 75% of the circumference of the neck. Figure 10A shows the dog one week after suturing of this wound in another veterinary clinic. Despite wound closure, drainage and antibiotic treatment, the entire suture line became

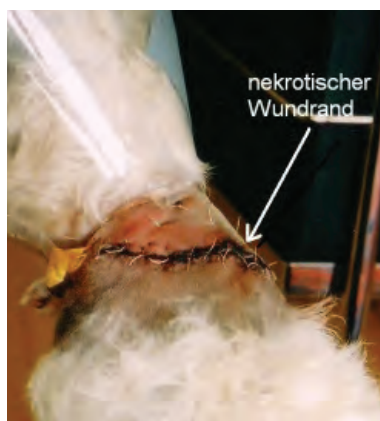

Figure 10A

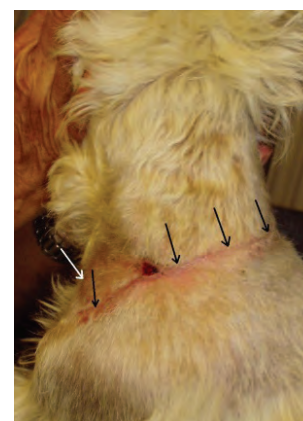


Figure 10B

Figure 10 (Case 9): A 6-year-old male Scottish Terrier bitten by a male Doberman that resulted in laceration of the skin over 75% of the circumference of the neck.

Figure 10A: Necrotic wound covering 75% of the circumference of the neck one week after initial suturing before dehiscence (see arrow).

Figure 10B: Photograph of the wound shown in Figure 10A, 12 days later after 4 laser treatments. Complete healing of the necrotic site has occurred without surgery and antibiotics (arrows). (Reprinted with permission from Petermann U., Pulse Controlled Laser Acupuncture Concept (PCLAC). 2007: www.akupunkturtierarzt.de)

necrotic. Two days later, when the dog presented for LA to the author's clinic, there was complete dehiscence and the wound was now 20x13cm. Over the course of 12 days, 4 laser therapy treatments were performed and the wound closed completely (Figure 10B). Each treatment involved LLLT of the wound using a 5x 30 Watt, 904nm impulse laser for 10 minutes. Acupoints TH-5, SP-4 (to treat infection) and SP-2 (to stimulate wound repair) were treated using a 90 Watt pulse laser for 30 seconds per point. No other surgical or medical interventions were required for complete healing.

DISCUSSION

Treatment of poorly healing, non-healing and infected wounds is a significant challenge in the management of traumatic and surgical wounds, especially if necrotizing organisms are present and or multiple drug resistance is involved. One of the major advantages of LLLT is that it can be used to treat wounds for which antibiotics and or surgery have proven ineffective. Since antibiotic resistance is not an issue, LLLT of infected tissue is a highly effective therapy. The anti-inflammatory effects of laser therapy occur through clearance of peroxide radicals in the infected tissues and activation of immune cells such as lymphocytes, macrophages and other inflammatory mediators.^{11,13} Selection of an appropriate laser is essential, as the laser used must penetrate deeply enough into the tissue for sufficient laser photons to reach the infected cells. At the time of writing, the 90 W, 904nm Impulse Physiolaser is the only available laser that provides this high energy and (therefore) used in this case series. In addition to the type and power of a laser, resonance frequencies play a fundamental role in determining success of treatment. For LLLT of diseased tissue, the Nogier frequencies are most commonly used: frequency A reduces inflammation; frequency B has a special affinity with ligaments, tendons and muscles; frequency C has an affinity with muscles, bones and joints; and frequency E stimulates nerve function. Bahr frequencies can also be used. These are especially useful for acupuncture diagnosis but can also be effective therapeutic frequencies. A third type of frequency, still relatively new, are Meridian frequencies described by Reininger. Reininger detected particular resonance frequencies for each acupuncture channel. These frequencies are not only important for treatment of all meridian acupoints but also for treatment of that channel's associated organ.^{12,14} Over the last 25 years, the author has successfully applied these frequencies to treat a variety of conditions in both dogs and horses.

Laser acupuncture has excellent treatment efficacy and allows pain-free and safe treatment of acupoints even in uncooperative patients^{15,16}. The greatest advantage of the use of impulse lasers in acupuncture is the synergy between the effects of acupuncture and LLLT. The local effects of LLLT support the autonomic regulating effect of acupuncture and vice versa, which appears to be especially

beneficial for wound healing. Impulse lasers with a 904nm wavelength and the new anti-inflammatory Nogier frequency A'' of 37376 Hz can sufficiently penetrate tissue to reduce peroxide radicals and generate ATP locally.^{4,5} The cost of the equipment may initially seem to be a disadvantage, but its ability to be used for both LA and LLLT makes the investment worthwhile.

Primary criteria for patient selection in this case series was the lack of clinical improvement from conventional therapy. All patients had been previously treated for 2 weeks to a year without success using conventional treatment modalities. Five of the patients had been recommended for euthanasia by the former treating clinic, 4 patients had a very poor prognosis for resolution of chronic wounds and 1 patient had a documented MRSA infection. These case reports are just a few examples from the hundreds of cases the author has successfully treated over the past 25 years and demonstrates that the combination of LA (as an autonomic regulating therapy) and LLLT (to reduce inflammation and stimulate healing) is an excellent alternative for treating non-healing wounds when conventional veterinary treatment is unsuccessful. More large-scale studies on the effects of LLLT and LA are still required, particularly studies directly comparing the efficacy of laser treatment (especially class 4 laser) with conventional treatment. In addition, laser therapy continues to show encouraging results when treating severe wound sepsis, including infections by MRSA and bacteria with multiple drug resistance as demonstrated in Case 2. It is the hope of the author that the technique described here will be used to treat more animals in the future, including those for whom euthanasia is being considered due to the severity of their wounds.

FOOTNOTES

- a. The Physiolaser Olympic 90 W/904nm, Reimers & Janssen, 14057, Berlin, Germany
 - b. LaserPen 40 W/904nm, Reimers & Janssen, 14057, Berlin, Germany
 - c. Rivanol® Powder, Dermapharm Arzneimittel AG, 82031 Grünwald, Germany
 - d. Arnica tincture Deutsche Homöopathie-Union, 76227 Karlsruhe, Germany
-

REFERENCES

1. Bergsmann O. Die biokybernetische Wirkung der Akupunktur im klinischen Versuch. Dtsch. Ztschr. f. Akup 1977; 5:131. (in German)
2. Heine H. Zur Morphologie der Akupunkturpunkte. Dtsch. Ztschr. Akup 1987; 30:75-79. (in German)
3. Xie H, Preast V. Xie's Veterinary Acupuncture. Ames, IA:Blackwell Publishing 2007:13-24.
4. Petermann U. Pulse controlled laser acupuncture concept (PCLAC) 2007; www.akupunkturtierarzt.de.
5. Petermann U. A holistic view of chronic disease

- with special consideration of adaptation syndrome and disturbing focus in controlled acupuncture. Proceeding of the 28th IVAS World Congress, Lihue, Hawaii, USA 2001:23-42.
6. Petermann U. Laser acupuncture in post-operative fields veterinary medicine. Proceedings of the 27th IVAS World Congress, Ottawa, Canada 2001:85-98.
 7. Petermann U. Laser therapy and laser acupuncture in wound healing, disturbances in common wounds and post-operative complications. Proceedings of the 29th IVAS World Congress, Santos, Brazil 2003:325-336.
 8. Petermann U. Kontrollierte Akupunktur für Hunde und Pferde. Stuttgart, Germany:Sonntag Verlag 2003. (in German)
 9. Skobelkin OK, Kozlov VI, Litvin G D *et al.* Blood microcirculation under laser physio- and reflexotherapy in patients with lesions in vessels of low extremities. LLLT-Reports 1990:69-77.
 10. Petermann U. Laserakupunktur bei infizierter tendinitis des pferdes. Prakt Tierarzt 1999; 1: 38-42. (in German)
 11. Mester E, Szenda B, Spiry T *et al.* Stimulation of wound healing by laser rays. Acta Chir Acad Sci Hung 1972; 13:315.
 12. Nogier PFM. Lehrbuch der Auriculotherapie. Sainte-Ruffine FR:Maisonneuve 1981.
 13. Karu T, Andreichuk T, Ryabykh T. Suppression of human blood hemi-luminescence by diode laser irradiation. Laser Therapy 1993; 5:103-109.
 14. Bahr F, Strittmatter B. (2010) Das große Buch der Ohrakupunktur. Hippkrates Verlag, Stuttgart 2010
 15. Dorsher, PT (2010) Clinical Equivalence of Laser Needle to Metal Acupuncture Needle in Treating Musculoskeletal Pain: A Pilot Study, Medical Acupuncture. 2010 March;22(1):11-17.
 16. Yurtkuran M. et al, (2007), Laser acupuncture in knee osteoarthritis: a double-blind, randomized controlled study. Photomed Laser Surg. Feb;25(1):14-20.