

Clinical Studies

Comparison of Pre- and Post-treatment Pain Scores of Twenty One Horses with Laminitis Treated with Acupoint and Topical Low Level Impulse Laser Therapy

Uwe Petermann DVM

ABSTRACT

Low-level impulse lasers have been applied focally to stimulate acupoints (laser acupuncture) and topically over wounds, joints and other tissues to increase circulation and promote healing. Laser acupuncture has been used to treat neck and back pain, tendonitis, osteoarthritis, injuries, chronic allergies, immune-mediated disorders, internal medical disorders and other diseases. Low level impulse laser therapy (LLLT) reduces inflammation and muscle spasms, increases blood perfusion and encourages clearance of peroxide radicals and healing in abscessed and degenerating tissues. Twenty one horses with laminitis were presented to the author for LLLT on acupoints and topically to encourage microcirculation and demarcation of abscesses of the hoof. Before and after completion of a series of LLLT treatments, each horse was evaluated and given a pain score based on a pre-determine pain scale. The mean \pm standard deviation of pre- and post-treatment pain scores were compared with a t-test and were significantly different at $p < 0.001$. Photographs of severe cases of laminitis in horses recommended for euthanasia are shown before and after LLLT. The results of this pilot study support the use of LLLT as a primary or adjunctive treatment option for equine laminitis and indicate the need for further exploration of LLLT for laminitis and other diseases in animals.

Key words: Laminitis, acupoints, acupuncture, low level impulse lasers, laser therapy, low level impulse laser therapy, LLLT, horse

ABBREVIATIONS

Hz	Hertz or cycles per second
LLL	Low level impulse laser
LLLT	Low level impulse laser therapy

Acupoints are small areas of reduced electrical resistance near the surface of the body consisting of a high concentration of free nerve endings and blood vessels within the fascia and muscles.^{1,2} Acupuncture stimulates nerves to evoke autonomic reflexes and neurohumeral changes via higher brain centers to restore homeostasis of the body.^{1,2} The acupoints effective for specific disorders of animals have been determined by hundreds of years of experience in traditional Chinese veterinary medicine (TCVM).³ Acupoints may be stimulated with pressure, dry needles, electricity, injections of substances, implantation of substances, moxa and lasers. Laser acupuncture is relatively new compared to the other forms of acupoint stimulation, but has advantages over dry needle acupuncture because it is usually painless and there is no need to touch the skin.⁴

Low level impulse laser (LLL) light at very specific wavelengths and pulse power, duration and frequencies can be applied focally over acupoints for laser acupuncture.⁴ One must be very careful to distinguish between the different resonance frequencies of the laser, the number of laser pulses sent out per sec, and the wavelength of the laser light used. Low level impulse laser therapy (LLLT) devices emit a high intensity short duration pulsing light with a wavelength of 903 nanometers (nm), a peak pulse power of 90 watts and duration of 200 nanoseconds (ns) (Figure 1). Tissue penetration of these impulse lasers is up to 15 cm because of the powerful light pulses, but because of their ultra-short duration, no thermal or coagulating effects occur in the tissue, even at high impulse frequencies up to 40,000 Hz. Acupoints need a treatment duration of 15-30 sec but topical treatment of the hoof wall and other wounds usually takes about 30 sec to 1 minute/square centimeter surface depending on the depth one has to reach.⁴

The LLL stimulation of acupoints has been used to treat neck and back pain, tendonitis, osteoarthritis, injuries, chronic allergies, immune-mediated disorders, internal medicine diseases and many other medical

From: Veterinary Acupuncture Clinic, Melle, Germany

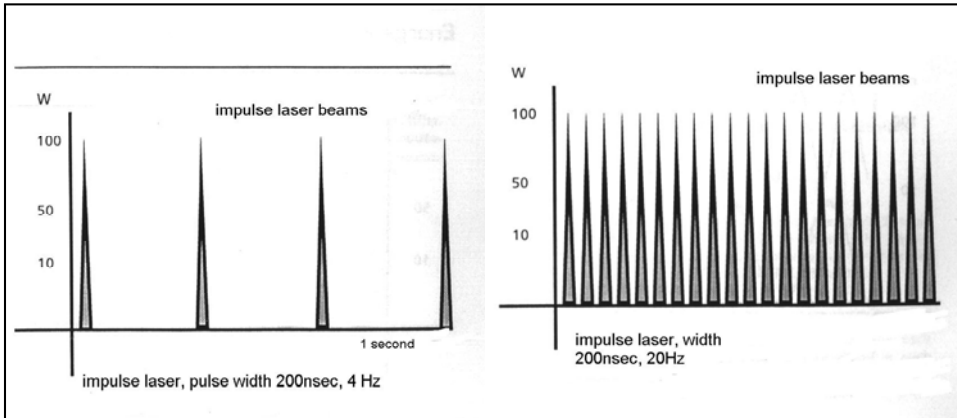


Figure 1: The strength, duration and frequency of light impulses emitted during low level impulse laser therapy with 90 Watts (W) energy output, duration 200 nanoseconds and frequency of 4Hz (left) and 20Hz (right).

conditions.⁴⁻¹¹ The LLL light has also been applied topically to wounds, joints, tendons and other tissues to reduce inflammation and muscle spasms, increase blood perfusion and promote collagen growth, nerve regeneration, demarcation of abscesses and wound healing.^{6,8,11,12}

In the 1970's, Dr. Paul Nogier, a noted French neurologist, studied the LLL frequencies that preferentially enter into resonance with different body systems, tissues and acupoints and provide the best therapeutic effects. He established the Nogier frequencies A-G (Table 1).¹³ Another noted laser researcher, Dr. Frank Bahr from Munich, Germany a student of Dr. Nogier's, suggested frequency ranges for

certain acupoints and tissues, Bahr 1-7, based on his experiments.¹⁴ The author (Petermann) studied with Dr. Bahr. The Nogier and Bahr frequency ranges are pre-programmed into all modern LLLT delivery units and are commonly used by LLLT practitioners, because they resonate well with acupoints and tissues and have excellent therapeutic effects.^{6,11,13,14} Modern therapeutic LLLT units have diode lasers scarcely bigger than a match-head, so are compact, portable and easy

to use. The Physiolaser Olympic unit^a with different probes and the LaserPen^a 40 W/904nm^a are two commonly used units (Figures 2a and 2b).^{4,11}

Laser photon absorption during LLLT is thought to stimulate nerve endings at acupoints and induce therapeutic effects via autonomic nervous system reflexes and higher brain centers similar to other forms of acupoint stimulation.¹⁰ The LLL appears to hyperpolarize local nerve endings and reduce muscle spasms and pain. During LLLT, laser photons can be directly absorbed into cells by means of a flavoprotein-metal-redox-system or a so called "antenna pigment", an important link within the mitochondrial respiratory pathways to stimulate adenosine triphosphate (ATP)

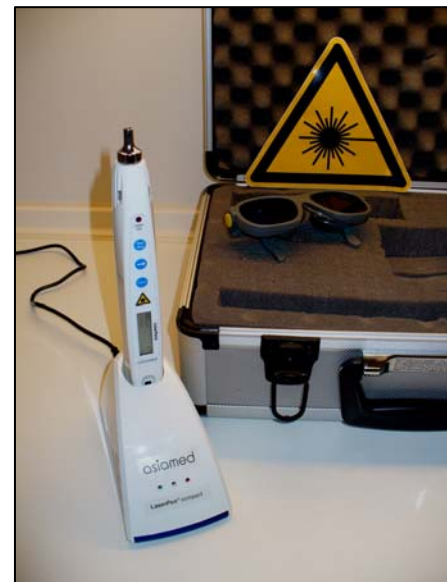
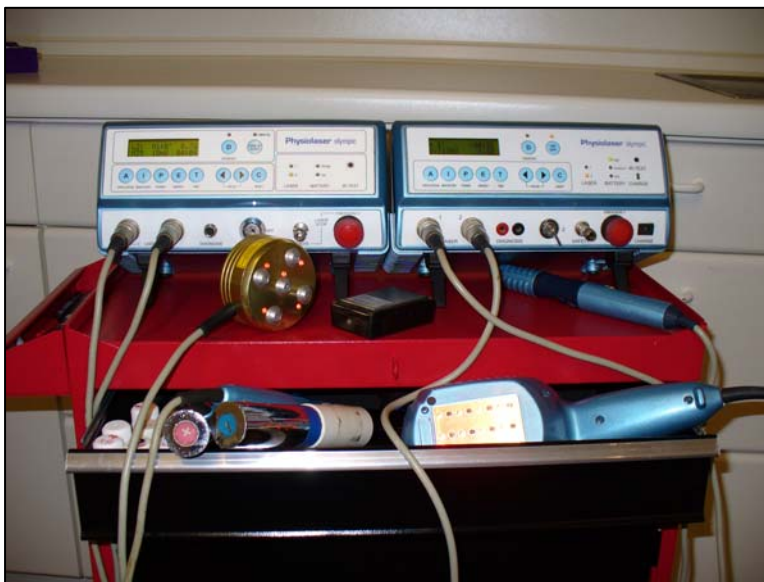
Figure 2a, left: Two Physiolaser Olympic low level impulse lasers units^a each with a single probe and a cluster probe. Both Physiolasers are connected with one 90 watt single probe for acupoint stimulation and topical therapy (A). The left unit also has a 5 x 30 watt impulse laser shower (B) and the left unit also has a 12x 10 watt impulse laser shower (C) for topical therapy; **Figure 2b, right:** Laser Pen^a 40 W/904nm for acupoint stimulation in charging station.

Table 1: The Nogier and Bahr frequencies used for low level impulse laser therapy

Nogier Frequencies							
Frequency Letter	A	B	C	D	E	F	G
Hz	292	584	1,168	2,336	4,672	73	146
Bahr Frequencies							
Frequency Number	1	2	3	4	5	6	7
Hz	599.5	1,199	2,398	4,796	9,592	19,184	38,368

Hz= hertz or cycles per second; Nogier¹³, Bahr¹⁴

production. Increased ATP production is the primary mechanism of laser acupuncture and topical therapy. Absorbed laser photons are transformed directly into cellular energy.^{4, 7-10} Diseased and damaged tissues require high levels of energy to absorb inflammatory secretions and other debris, synthesize new structures, rebuild damaged tissue and return to normal function. The LLLT is thought to contribute to the rebuilding and healing process by increasing energy production within diseased cells. Another important therapeutic property of the laser light is its ability to improve blood perfusion in micro-circulatory disorders.¹²

Laminitis in horses is associated with a transient ischemia and coagulopathy of the sensitive laminae of the hoof that results in thromboemboli formation within capillary beds, hypoxia and necrosis.¹⁶ Laminitis may be induced by excess consumption of carbohydrate rich grains and lush grasses and hoof trauma or secondary to colic, enteritis, endotoxemia, postparturient metritis and corticosteroids or other drug administration. Clinical signs in acute laminitis include depression, anorexia, fever, lameness and a reluctance to stand or support weight on the affected foot or feet. An exaggerated, bounding digital artery pulse may be palpated or observed. The hoof is hot especially around the coronary band and the sole is painful, when pressure is applied. Chronic laminitis occurs from multiple episodes of acute laminitis and is a common cause of lameness in horses. Pedal bone rotation occurs in both acute and chronic forms and may penetrate the sole in front of the frog. Secondary hoof infections may occur. The LLLT acupoint stimulation has local effects and restores balance systemically to promote healing. Topical LLLT of open wounds associated with laminitis improves microcirculation and provides energy for tissue debris removal and re-building. Acupoint and topical LLLT is a rational adjunctive or primary therapy for laminitis.

The objective of this prospective clinical trial was to treat all horses presented with laminitis during 2008-2009 with acupoint and topical LLLT, without conventional oral or injectable medication, and compare pre- and post-treatment pain scores to determine if the LLLT would significantly reduce the clinical signs of equine laminitis.

MATERIALS AND METHODS

Twenty one horses with laminitis were presented to the author for LLLT (Table 2). Eighteen of the horses were presented during 2008-2009. Three additional horses recommended for euthanasia due to extremely severe laminitis with open wounds were added to report the effects of LLLT even in the most severe cases considered hopeless by conventional medical standards (Table 2, horses 19 [2001], 20 [2006] and 21 [2003]). A diagnosis of laminitis was based on the history and physical examination findings, which included foot tenderness when walking, pain when turning, severe bilateral lameness often in the thoracic limbs, redness and widening of the hoof's white line (the inner layer of the hoof wall visible on the sole), pulsation of the digital arteries and sole pain on palpation or when pressure was applied with a hoof tester. In three horses pedal bone rotation was present on radiographs (Table 2, Horses 16, 19 and 21). Prior to treatment, each horse was evaluated and given a pain score based on the pre-determined pain scale created by the author, modified from other pain scales, listed in Table 3. Antihistamines, antibiotics, non-steroidal anti-inflammatory drugs, corticosteroids or any other conventional therapy were discontinued at the onset of LLLT.

The Physiolaser Olympic 90 W/904 nm^a and the LaserPen 40 W/904nm^a were the LLLT units used in the study (Figures 2a and 2b). Eleven acupoints were treated with LLLT and the acupoints, rationale for selection,

Table 2: Overview of the signalment, duration of signs, number of treatments and pre-treatment and post-treatment pain scores of twenty one horses with acute or chronic laminitis, treated with low level impulse laser therapy at acupoints and topically on the hoof wall

Horse No.	Breed	Age (years)	Sex	Duration of signs	Previous treatment	Number of treatment sessions	Pain score 1	Pain score 2	Time between pain scores (weeks)
1	Welsh pony	15	Gelding	Chronic	Yes	5*	3	1	4
2	Haflinger	13	Gelding	Acute	No	4	3	1	3
3	Hanoverian	19	Gelding	Acute	Yes	4	4	1	3
4	Shetland pony	13	Mare	Acute	No	8	5	2	3
5	New Forest	13	Gelding	Acute	Yes	4	3	1	3
6	Westfalen	17	Mare	Acute	Yes	6	4	1	4
7	Hanoverian	11	Gelding	Acute	No	5	3	1	2
8	Island pony	16	Gelding	Acute	No	3	3	1	5
9	Shetland pony	7	Mare	Chronic	Yes	10*	4	1	4
10	Sachsen Anhalt	9	Gelding	Chronic	No	5	3	1	3
11	Quarter horse	6	Mare	Acute	No	3	3	2	3
12	Arabian	13	Mare	Chronic	No	3	3	1	4
13	Westfalen	5	Mare	Acute	No	3	2	1	2
14	Westfalen	14	Gelding	Acute	No	3	2	1	2
15	German Riding pony	15	Gelding	Chronic	Yes	17	4	1	5
16	Oldenburg	14	Mare	Acute	Yes	3	3	1	3
17	Hanoverian	1	Stallion	Acute	Yes	8*	5	1	5
18	Fjord horse	22	Gelding	Chronic	Yes	5*	4	1	6
19	Hanoverian	11	Mare	Acute	Yes	4*	3	1	4
20	Arabian	7	Gelding	Acute	No	9	5	1	4
21	Trakehner	17	Mare	Chronic	Yes	19*	5	2	6

Acute= clinical signs less than 14 days, Chronic= clinical signs greater than 14 days, Previous treatment=conventional drug therapy given prior to the low level impulse laser therapy (LLLT); All horses received LLLT acupuncture and topical LLLT treatment for the hoof wall for each treatment session. *Horses that also received daily topical treatment in the hospital and at home by caretakers; Pain score 1= initial pain score prior to LLLT; Pain score 2= pain score at the end of LLLT.

laser frequencies and duration of treatment for each are listed in Table 4. A 90W impulse laser single probe and a 40 W impulse laser pen was used for acupoint stimulation and the tip of the laser device was placed directly on each acupoint for 20 seconds. Two 90 W impulse single probes and a 5x30w impulse laser cluster probe was used for topical treatment of the hoof wall and wounds and the probes were held as close as possible to

the wound without directly touching to avoid contaminating the laser tip or the wound. Topical LLLT took 2-5 minutes of treatment for each hoof (Figure 3).

The total diagnosis and LLLT treatment time per session was usually 30-40 minutes. Between LLLT sessions, the affected hooves were bandaged with wet dressings of aluminum acetate^b (50g/L), and *arnica* tincture^b (10ml/L). The dressing was changed after every

Table 3: Pain scale used to evaluate horses prior to and at the completion of the low level impulse laser therapy of acupoints and hoof in horses with laminitis

Pain Score	Description of Clinical Signs
1	No lameness during any gait, no digital artery pulsation, no sole pain with hoof tester pressure
2	Mild lameness when trotting, mild pain when turning, slight pulsation of the digital arteries, minor sole pain with hoof tester pressure
3	Moderate lameness when trotting, moderate pain when turning, moderate pulsation of the digital arteries, moderate sole pain with hoof tester pressure
4	Severe lameness when walking and trotting, strong pulsation of the digital arteries, severe sole pain with hoof tester pressure
5	Patient is mostly lying down due to severe foot pain and is barely able to take steps, very strong pulsation of the digital arteries

treatment and a cast bandage was molded on twice daily (Figure 3).

The frequency and overall number of treatments varied with the individual needs of the affected horse. In the acute cases, LLLT was repeated every 2 -3 days until the pain score was reduced to at least 2. Then the

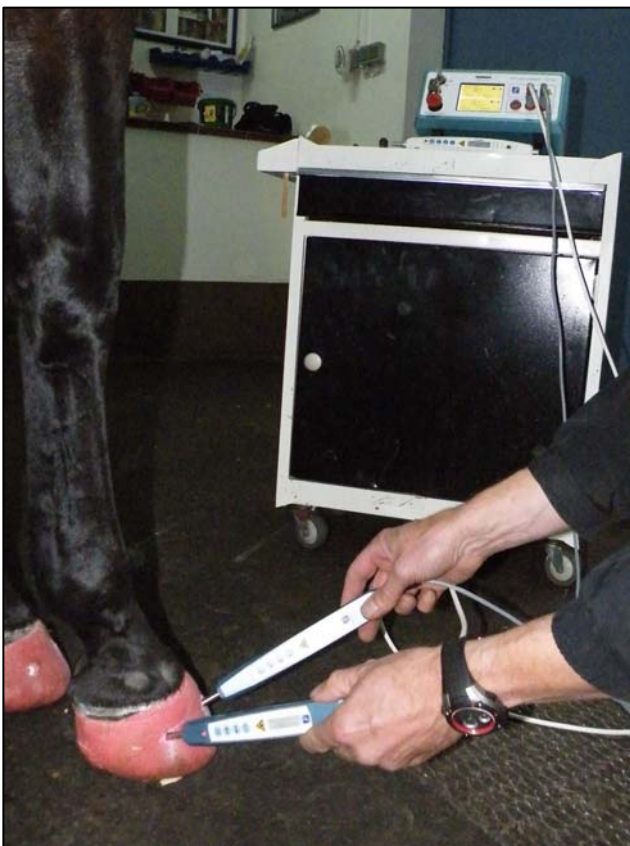

Figure 3: Treatment of the hoof with two 90 watt impulse laser single probes 90 W/904 nm attached to a Physiolaser Olympic^a (background) in a horse with laminitis. Areas of the cast bandage have been opened in order to apply the laser therapy to the hoof wall.

treatment intervals were extended to one week. In severe cases in which there was danger that the entire hoof wall could be lost, LLLT of the acupoints and topically of the hoof was administered daily. If there were open wounds, daily LLLT was given topically in the hospital and once the horse had improved, the horse was discharged from the hospital and after detailed instruction, the owner continued daily treatments at home using a 90W impulse laser, the same as that used in the clinic.

All horses were examined after the LLLT treatment series was completed and a second pain score was given for each horse based on the pre-determined pain scale outlined in Table 3. All pre-treatment and post-treatment scoring and acupoint LLLT was performed by one investigator (the author). The mean and standard deviations ($M \pm SD$) of the pre- and post- treatment pain scores were calculated and compared using a paired t-test^c for all 21 horses treated, 18 horses treated in 2008-2009, 14 horses with acute laminitis and 7 horses with chronic laminitis. A *p*-value of < 0.01 was considered significant.

RESULTS

An overview of the signalment of the 21 horses with laminitis treated with LLLT is summarized in Table 2. There were 11 geldings, 9 mares and 1 stallion. Fifteen different horse breeds were represented. There were 10 warmblood horses, 8 ponies, 2 Arabians and 1 Quarter horse. The ages ranged from 1-22 years (mean 12.3 years). Acute laminitis was diagnosed, if the clinical signs were present less than 14 days and chronic, if the clinical signs were present 14 days or more. Seven horses had suffered from chronic laminitis and were presented for laser acupuncture because of an acute attack. Six horses had been treated for acute laminitis with conventional treatment, but were presented for laser acupuncture, because the clinical signs had worsened. Eight horses with acute laminitis came directly for laser acupuncture with no prior conventional treatment. The number of treatments ranged from 3-19 with a mean of

Table 4: Acupoints treated and their indications and strength, wavelength and frequencies of the low level impulse laser therapy at each acupoint suggested by authors Nogier and Bahr and used to treat horse with laminitis in this study

Acupoints	TCVM	Other	Laser strength (W)	Laser wave-length (nm)	Pulsing frequency (Hz)	Treatment time (seconds)
TH-1	TH Metal point	Ting point	90	903	1,168	20
PC-9	PC Wood point	Ting point	90	903	1,168	20
LU-9	LU Tonifying point	Blood perfusion	90	903	1,168	20
BL-40	BL Earth point	Histamine point	90	903	1,168	20
LIV-8	LIV Tonifying point	Liver point	90	903	584	20
KID-7	KID Tonifying point	Kidney point	90	903	584	20
GB-41	Opening point <i>Dai-mai</i>	Prostaglandin E1	90	903	9,592	20
TH-5	Opening point <i>Yang-wei-mai</i>	Thymus point	90	903	9,592	20
BL-18	LIV Back <i>Shu</i> Association point	Sympathetic Liver	90	903	1,168	20
BL-23	KID Back <i>Shu</i> Association point	Sympathetic Kidneys	90	903	1,168	20
LIV-13	SP Front <i>Mu</i> Alarm point	ACTH point	90	903	1,168	20

W=watts, nm=nanometers, Hz= hertz or cycles per second; 1,168 Hz=Nogier C, 584 Hz =Nogier B, 9,592 Hz =Bahr 5

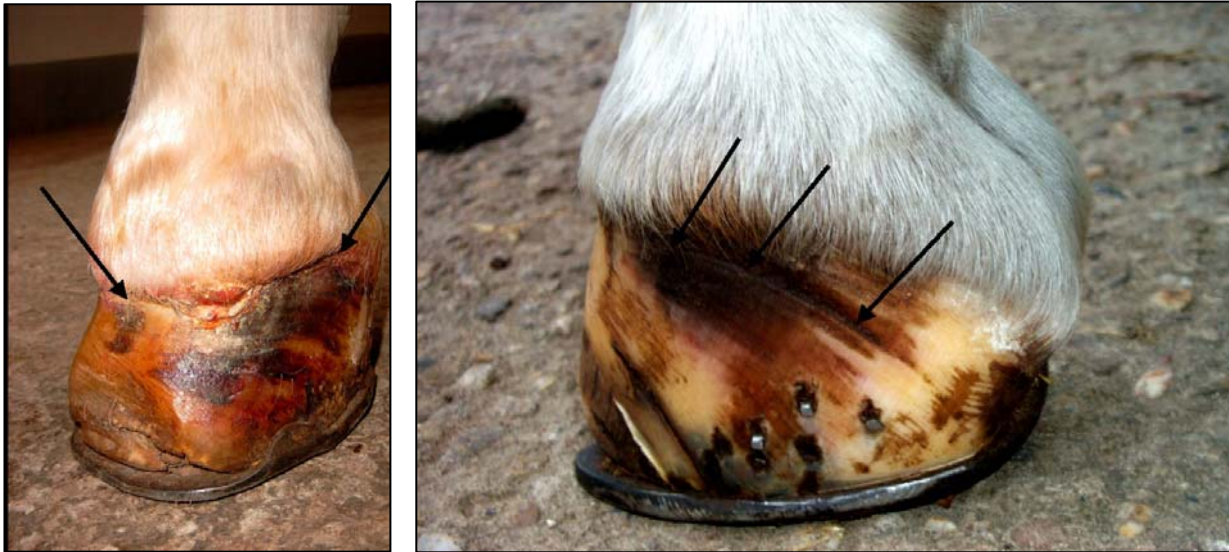6.2 treatments for all 21 horses. Eighteen patients had both reduced lameness and digital artery pulsation when they were seen for the third treatment. Three patients, with pain scores of 5, needed more treatment sessions before improvement was seen (Figures 4-7).

Six of the 21 horses, horse numbers 1, 9, 17, 18, 20 and 21, received one, one, three, two, three and two weeks respectively of caretaker daily LLLT at home (Table 2, Figures 4-7). Horses number 4 and 11 had a pain score of 2 at the end of the treatments, but according to their caretakers became sound within 14 days after their last treatment (Table 2). Eighteen out of 21 (85.5%) horses became sound after treatment. Six horses in the study (horse numbers 1, 2, 3, 6, 8 and 10) developed mild clinical signs of laminitis again within 6-18 months, but within 2-3 treatments they were again sound. Eight horses (horse numbers 1, 3, 5, 7, 9, 16, 18 and 21) were treated with laser acupuncture prophylactically every 5 - 8 months and have had no further problems.

The time between evaluation of the pre-treatment and post-treatment pain scores ranged from 2-6 weeks with a M±SD of 3.71±1.19 weeks. A summary of the range and M±SD of the pre- and post-treatment pain scores and t-test comparisons of the M±SD for all 21 horses, only the 18 horses treated in 2008-2009, the 14

horses with acute laminitis and the 7 horses with chronic laminitis are shown in Table 5. The pre-treatment scores of all 21 horses with laminitis ranged from 2-5 with a M±SD of 3.52±0.93 and the post-treatment scores ranged from 1-2 with a M±SD of 1.14±0.36 (Tables 2 and 5, Figure 9). Comparing the means of the pre- and post-treatment pain scores of the 21 horses with an paired t-test, there was a significant reduction of the pain score after LLLT of $p<0.001$. The pre-treatment scores of the 18 horses treated between 2008-2009 ranged from 2-5 with a M±SD of 3.39±0.85 and the post-treatment scores ranged from 1-2 with a M±SD of 1.11±0.32 (Tables 2 and 5). Comparing the means of the pre- and post-treatment scores of the 18 horses, (treated during 2008-2009) with a paired t-test, there was a significant reduction of the pain score after LLLT of $p<0.001$.

The pre-treatment scores of 14 horses with acute laminitis ranged from 2-5 with M±SD of 3.43±1.02 and post-treatment scores ranged from 1-2 with a M±SD of 1.14±0.36 (Tables 2 and 5, Figure 10). Comparing the means of the pre- and post-treatment scores of the 14 horses with acute laminitis with a paired t-test, there was a significant reduction of the pain score after LLLT of $p<0.001$. The pre-treatment pain scores of 7 horses with chronic laminitis ranged from 3-5 with a M±SD of 3.71±0.76 and the post-treatment scores ranged from 1-2



Figures 4a (left) and 4b (right): A 17 year old Trakehner mare (Table 2 number 21) with severe lameness from chronic laminitis of the left front foot. There was severe swelling and a suppurative infection at the coronary band with a 12 cm separation from the hoof wall (Figure 4a arrows). Euthanasia was recommended by the local veterinarian. The pre-treatment pain score was 5. The horse was hospitalized and received LLLT on acupoints and daily topical wound LLLT with a 90 watt pulse laser at a pulse rate of 292 and 9,592 Hz (Nogier's former anti-inflammatory frequency A and Bahrs anti-inflammatory frequency) for 3 minutes for 2 weeks. Astringent wet hoof bandages containing acridine dye solution were applied daily. The horse was discharged and the owner continued the topical laser treatment daily for 4 more weeks. After 6 weeks all suppuration was gone and a 1.5 cm zone of healthy hoof wall was present at the original wound site (Figure 4b arrows) and the pain score was 2. It has been 8 years and the mare continues to have a high quality of life, runs in the pasture without apparent lameness and can be occasionally ridden.

with a $M \pm SD$ of 1.14 ± 0.38 (Tables 2 and 5, Figure 11). Comparing the means of the pre- and post-treatment scores of these 7 horses with a paired t-test, there was a significant reduction of the pain score after LLLT of $p < 0.001$.

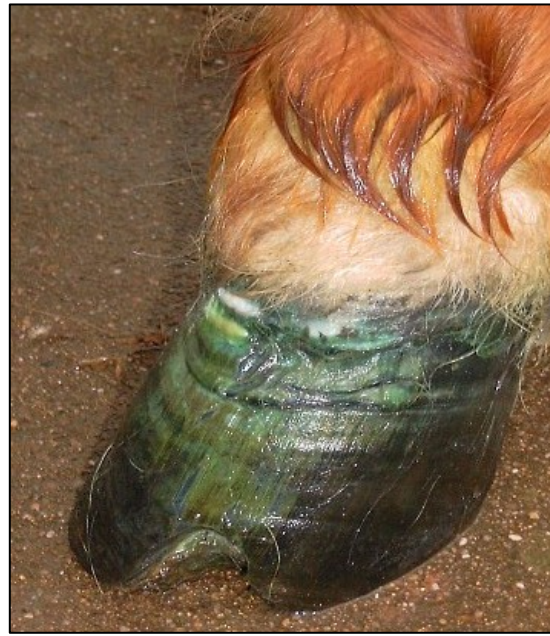DISCUSSION

Laminitis is associated with metabolic and micro-circulatory disorders of the hoof wall with inflammation of the coronary band and sensitive laminar portion under the thickly keratinized exterior surface of the hoof.¹⁶ From a TCVM perspective, laminitis is associated with

Blood Stagnation and an underlying Liver and Kidney Deficiency. The aim of therapy is to eliminate the disturbances in Liver and Kidney metabolism, reduce local histamine release, inflammation, edema and pain and to improve blood perfusion. Acupoints were chosen for LLLT based on their abilities to resolve the local and underlying pathological changes in laminitis and promote a return to normal function. The acupoints TH-1 and PC-9 were chosen because of their location around the coronary band and their local effects to reduce pain and inflammation and increase blood perfusion. The acupoint LU-9, as an influential point of pulse and

Table 5: Comparison of the means \pm standard deviations ($M \pm SD$) of the pre- and post-treatment pain scores of horses treated with low level impulse laser therapy

Group	Number of Horses	Pre-treatment $M \pm SD$	Post-treatment $M \pm SD$	Paired t-test p -value
All horses with laminitis	21	3.52 ± 0.93	1.14 ± 0.36	< 0.001
Laminitis in 2008-2009	18	3.39 ± 0.85	1.11 ± 0.32	< 0.001
Acute laminitis	14	3.43 ± 1.02	1.14 ± 0.36	< 0.001
Chronic laminitis	7	3.71 ± 0.76	1.14 ± 0.38	< 0.001



Figures 5a (Left) and 5b (right): A thirteen year old Shetland pony (Table 2, horse number 4) with a hoof abscess that had separated one third of the entire coronary band from the hoof wall. The pony could hardly stand and laid down in the stable most of the day. The pre-treatment pain score was 5. The abscessed region was opened and debrided. Along with the LLLT acupuncture as described in Tables 2 and 4, daily topical laser wound treatment with a 90 watt pulse laser at a pulse rate of 37,376 Hz (Nogier's anti-inflammatory frequency A) for 3 minutes was administered. Astringent wet hoof bandages with an acridine dye solution were applied daily. After six treatments every 2-3 days, the pony was trotting around the pasture without lameness and the wound was closed and healing (Figure 3b). The post treatment pain score was 2.

vessels, increases micro-circulation and BL-40 has anti-histaminic effects.^{4,14} The acupoint GB-41 stimulates prostaglandin E1 production to reduce inflammation, TH-5 stimulates the immune system and is the partner point (opening point) to GB-41 and LIV-13 stimulates adrenocorticotrophic hormone (ACTH) production.^{4,14} The acupoints LIV-8 and KID-7 tonify the Liver and Kidney respectively to restore balance to these organs and BL-18 and BL-23 are the Back *Shu* Association points to further restore homeostasis to these organ systems.

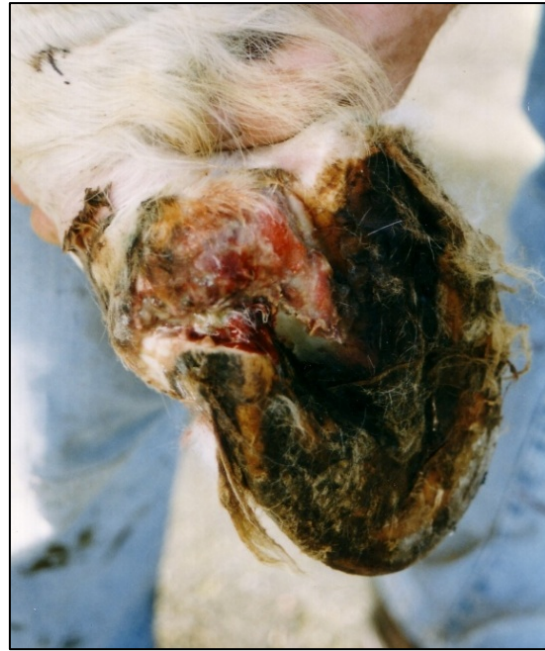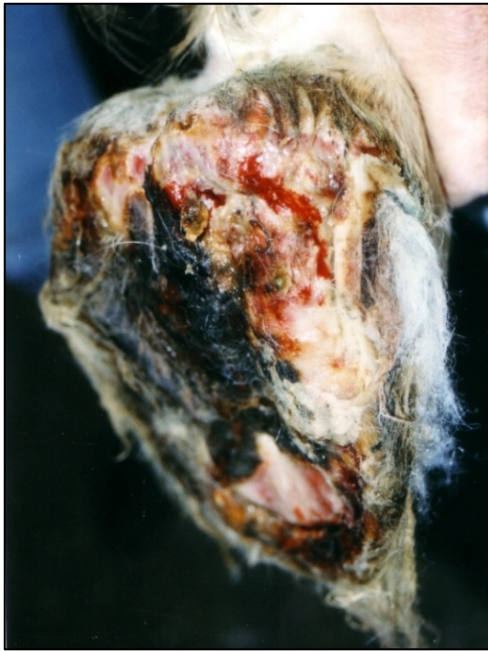Treatment of both acute and chronic laminitis with LLLT can significantly affect the pain associated with laminitis as evidenced by the statistical comparison of the pre-treatment and post treatment pain scores. After treatment the lameness and exaggerated digital artery pulsations improved in all horses and completely resolved in 18/21 horses. The number and frequency of treatments varied based on the individual needs of the horse as that is the reality of treating naturally occurring diseases in veterinary practice. A single treatment plan may not be the best approach for an individual animal and treatment is always modified based on response to therapy in the practitioner's judgment.

The LLL frequencies used to treat each acupoint in this study depended on their function and corresponded to those recommended by Nogier and Bahr in humans (Table 4).^{13,14} Over the last 25 years the author has

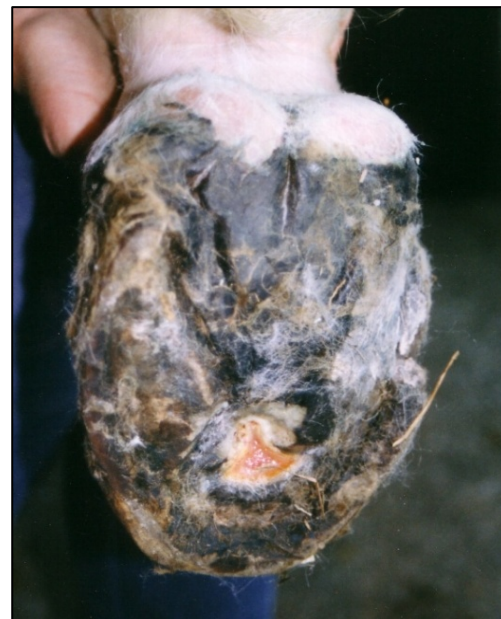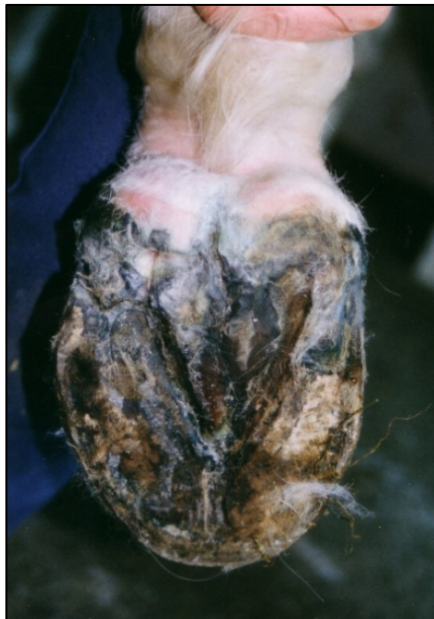applied these recommendations to treat dogs and horses for a variety of conditions. Both needle acupuncture and LLL acupuncture have the same treatment effects and time required for treatment, but LLL acupuncture may allow treatment of acupoints too painful for needles or more difficult to safely treat in some uncooperative horses. The greatest advantage of the use of impulse lasers in acupuncture is the synergy between the effects of the acupuncture and LLLT. The local effect of LLLT supports the vegetative regulating effect of acupuncture and vice versa, which together seem to be especially effective in chronic disease. The cost of the equipment may seem to be a disadvantage initially, but the ability to help animals with both LLL acupuncture and topical treatments makes the investment worthwhile.

Impulse lasers, with the new anti-inflammatory frequency A of 37,376 Hz, can sufficiently penetrate the exterior keratinized hoof wall to locally treat the inflamed inner laminae.⁴ The new frequency A of 37,376 Hz has an advantage over the formerly used frequency A (292 Hz), as it sends out much more laser energy per second (by approximately a factor of 150) and therefore decreases the treatment time from about 20 minutes to approximately 30 sec, yet still brings in enough therapeutic energy into the tissue.¹⁷

Although the overall case number was small, it was



Figures 6a (left) and 6b (right): A seven year old Arabian gelding with bilateral acute necrotic laminitis that occurred 3 days after a routine castration (Table 2, horse number 20). The horse had severe pain with a pain score of 5 and walked with difficulty with his weight shifted mainly onto the front feet. Large areas of necrosis were found on the caudal medial aspect of both the right (Figure 6a) and left (Figure 6b) hind feet in the area of KID-1. Euthanasia was considered, but the caretakers wanted to try LLLT first. The necrotic tissue was debrided. Along with the LLLT acupuncture as described in Tables 2 and 4, daily topical laser wound treatment with a 90 watt pulse laser at a pulse rate of 37,376 Hz (Nogier's anti-inflammatory frequency A) for 3 minutes was administered. The castration wound and an infected 3rd molar were also treated topically with LLLT. The feet were bandaged daily with antiseptic wet dressings containing homeopathic dilutions of calendula, echinacea and arnica. Within 2 days the pain had decreased and the necrotic areas were already improving.



Figures 6c (left) and 6d (right): The right hind foot (Figure 6c) and left hind foot (Figure 6d) of the same 7 year old Arabian gelding in Figures 6a and 6b three weeks after beginning LLLT treatment. The right hind foot had completely healed and the left hind foot had only a small area of ulceration remaining. Both feet completely recovered and the post treatment score was 1, four weeks after beginning treatment. It has been five years and the horse has never had further hoof problems.

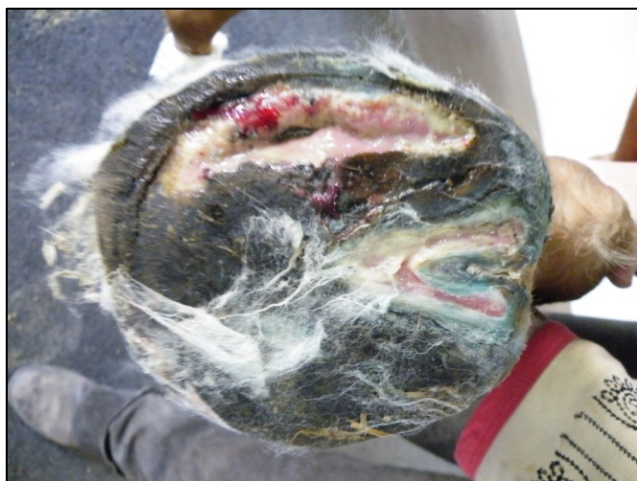

Figure 7a: A 1 year old stallion Hanovarian Stallion (Table 2, horse number 17) developed traumatically induced laminitis of both front feet after trying to escape from a moving horse van and dragging the hooves for approximately 500 meters on the tarmac. Besides the scratching of both soles, a necrotic, infected lesion developed on the right sole four days later. The entire medial area of the right sole was necrotic so that the pedal bone was exposed (Figure 7 a) and euthanasia was recommended by the local veterinarian. The owner elected to try laser treatments. The pre-treatment pain score was 5. The horse was sedated and a nerve block of the foot was performed so debridement of the wound could occur. Along with the LLLT acupuncture as described in Tables 2 and 4, daily topical laser wound treatment with a 90 watt pulse laser at a pulse rate of 37,376 Hz (Nogier's anti-inflammatory frequency A) for 3 minutes was administered for 10 days and continued by the caretaker at home for another week. Astringent wet hoof dressings containing an acridine dye solution were applied daily. The wound and lameness improved, but on re-evaluation a piece of sequestered bone was found in the center of the wound (Figure 7b).



Figures 7b (top) and 7c (bottom): The piece of sequestered bone found in the healing wound of the 1 year old Hanovarian Stallion in Figure 7a (Figure 7b) with traumatic laminitis. Four weeks later at the completion of LLLT the sole lesion had completely healed (Figure 7c) and the pain score was 1.

clear from this study that LLLT acupoint stimulation and topical therapy, without conventional therapy, significantly improved the clinical signs, halted disease progression and enhanced the quality of life of many horses even in horses with severe clinical signs and hoof pathology. The author has been successfully treating laminitis in horses with LLLT for over twenty years and performed this prospective clinical study of laminitis horses treated with LLLT within a one year time period to statistically evaluate his clinical impressions. It is the hope of the author that the technique reported here will be used to help horses with laminitis even though euthanasia is being considered, because of the severity of their disease.

Further studies on LLLT for laminitis are needed using a larger population of horses, compared with a group of conventionally treated horses and with outcome

evaluations performed by an individual blinded to the type of treatment. The latter type of study would have been difficult for the author, a busy solo practitioner, but the results of this pilot study support the use of LLLT as another treatment option for equine laminitis and indicate the need for further exploration of LLLT for laminitis and other diseases in animals.

FOOTNOTES

^a Physiolaser Olympic, Reimers und Janssen, Berlin, Germany

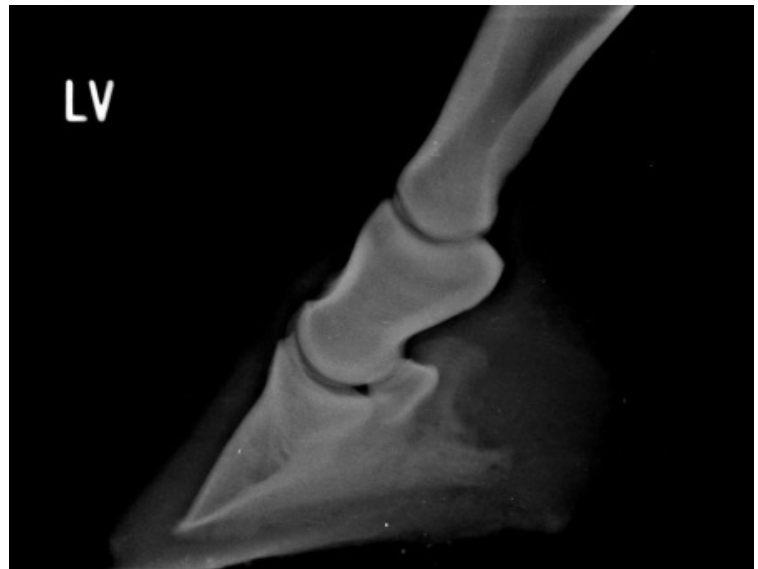
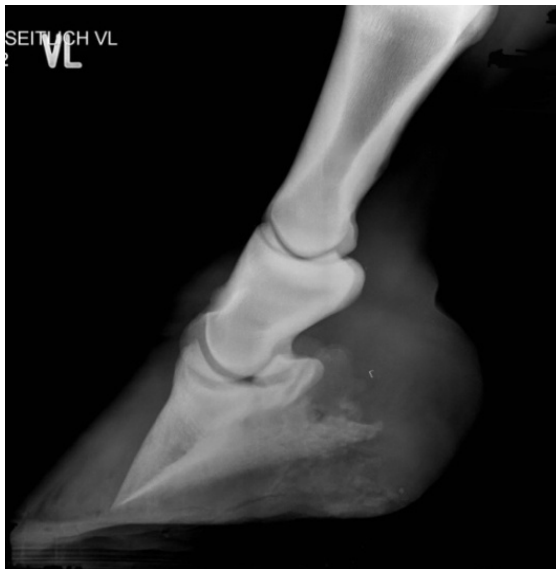^b Plantavet, Bad Waldsee, Germany

^c Paired t-test, <http://www.graphpad.com/quickcalcs/ttest2.cfm>

REFERENCES



Figures 8a (left) and 8b (right): An 11 year old Hanoverian mare (Table 2, horse number 19) developed acute laminitis at the beginning of the pasture season. The mare was very sensitive on both front feet and had a pain score of 3. Rotation of the pedal bone was seen on radiographs (Figure 8c). Along with the LLLT acupuncture every 3-4 days as described in Tables 2 and 4, topical LLLT with a 90 watt pulse laser at a pulse rate of 9,592 Hz (Bahr frequency 5 as at that time the new 37,376 Hz A” frequency was not yet available) was administered for 3 minutes for 2 weeks. The owner continued topical LLLT at home for 2 more weeks. The hooves were expertly trimmed and the tip of the toe was reduced. Within 4 weeks the mare was sound with a pain score of 1 and the hoof was returning to normal (Figure 8b). The horse returned to training 2 weeks later. Another radiograph of the hoof was obtained 4 months after the LLLT had been initiated and the pedal bone rotation had improved greatly and was now parallel to the sole (Figure 8d). For the past year the mare has been successfully competing in dressage tournaments and has required no further treatment.



Figures 8c (left) and 8d (right): The 11 year old Hanoverian mare (Table 2, horse number 19) with acute laminitis shown in Figures 8a and 8b. The laminitis and rotation of the left front pedal bone was obvious on radiographs prior to LLLT (Figure 8c). Four months after LLLT and corrective hoof trimming, the laminitis had resolved and the pedal bone was resuming its normal position parallel with the sole (Figure 8d).

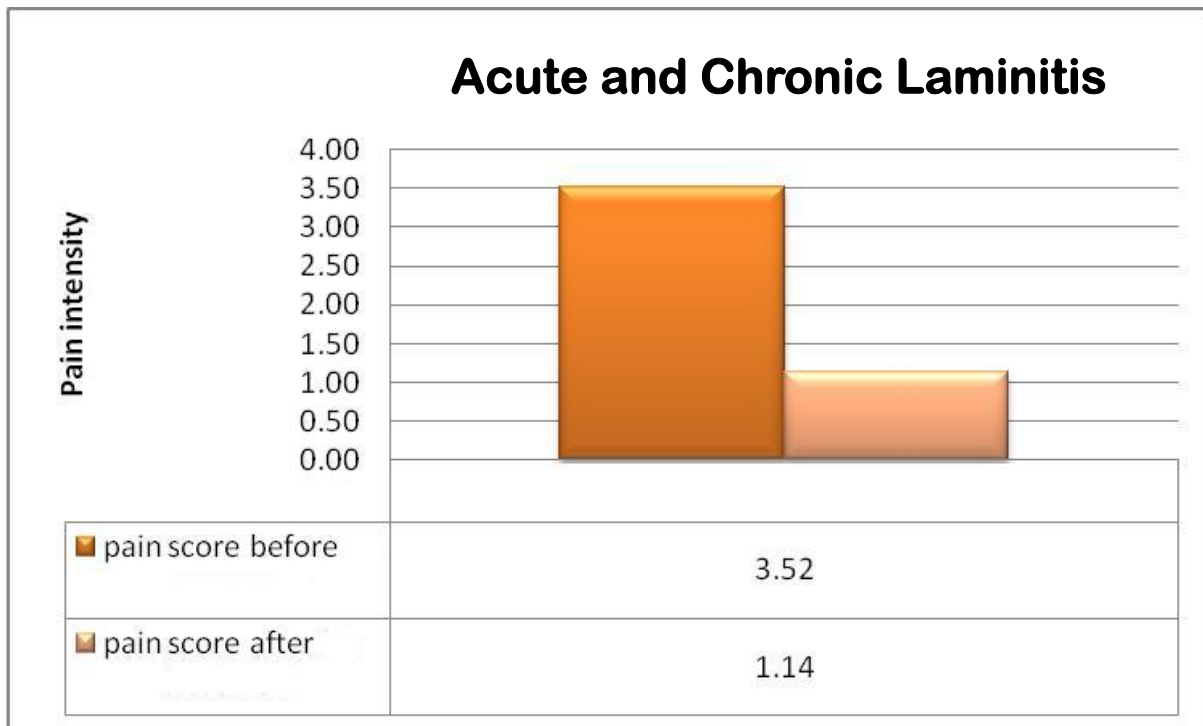


Figure 9: Comparison of pain scores before and after LLLT acupuncture (LA treatment) with or without topical wound treatment for twenty one horses with either chronic or acute laminitis (mean and standard deviation pre= treatment score 3.52 ± 0.93 and post-treatment pain scores 1.14 ± 0.36 , paired t-test= $p < 0.001$)

1. Bergsmann O. Die biokybernetische Wirkung der Akupunktur im klinischen Versuch. Dtsch. Ztschr. f. Akup 1977; 5:131. (in German)
2. Heine H. Zur Morphologie der Akupunkturpunkte. Dtsch.Zschr.Akup 1987; 30:75-79. (in German)
3. Xie H, Priest V. Veterinary Acupuncture. Ames, IA:Blackwell Publishing 2007:13-24.
4. Petermann U. Pulse controlled laser acupuncture concept (PCLAC) 2007; www.akupunkturtierarzt.de.
5. Karu T, Andreichuk T, Ryabykh T. Suppression of human blood hemi-luminescence by diode laser irradiation. Laser Therapy 1993; 5:103-109.
6. Mester E, Szenda B, Spiry T, Scher A. Stimulation of wound healing by laser rays. Acta Chir Acad Sci Hung 1972; 13:315.
7. Petermann U. Laser acupuncture in post-operative fields veterinary medicine. Proceedings of the 27th IVAS World Congress, Ottawa, Canada 2001:85-98.
8. Petermann U. Laser therapy and laser acupuncture in wound healing, disturbances in common wounds and post-operative complications. Proceedings of the 29th IVAS World Congress, Santos, Brazil 2003:325-336.
9. Petermann U. Kontrollierte Akupunktur für Hunde und Pferde. Stuttgart, Germany:Sonntag Verlag 2003. (in German)
10. Petermann U. A holistic view of chronic disease with special consideration of adaptation syndrome and disturbing focus in controlled acupuncture. Proceeding of the 28th IVAS World Congress, Lihue Hawaii, USA 2001:23-42.
11. Petermann U. Laserakupunktur bei infizierter tendinitis des pferdes. Prakt Tierarzt 1999; 1: 38-42. (in German)
12. Skobelkin OK, Kozlov VI, Litvin G D et.al. (1990) Blood Microcirculation under laser physio-and reflexotherapy in patients with lesions in vessels of low extremities. LLLT-Reports 1990:69-77.
13. Nogier PFM. Lehrbuch der Auriculotherapie. Sainte-Ruffine FR:Maisonneuve 1981.
14. Bahr F. Scriptum systematik und praktikum der wissenschaftlichen akupunktur für weit fortgeschrittene und Experten. München, Germany: Textbook, Eigenverlag 1997:19,20. (in German)
15. Warnke U. Der Dioden-Laser, Deutsches Ärzteblatt 1987; 44:2941-2944. (in German)
16. The Merck Veterinary Manual 9th Ed. Whitehouse Station, NJ: Merck & Co., Inc 2005:906-908. <http://www.merckvetmanual.com>.
17. Petermann U. The four pillars of pulse controlled laser acupuncture concept. Proceedings of the 36th IVAS World Congress, Aalborg, Denmark 2010:231-247.

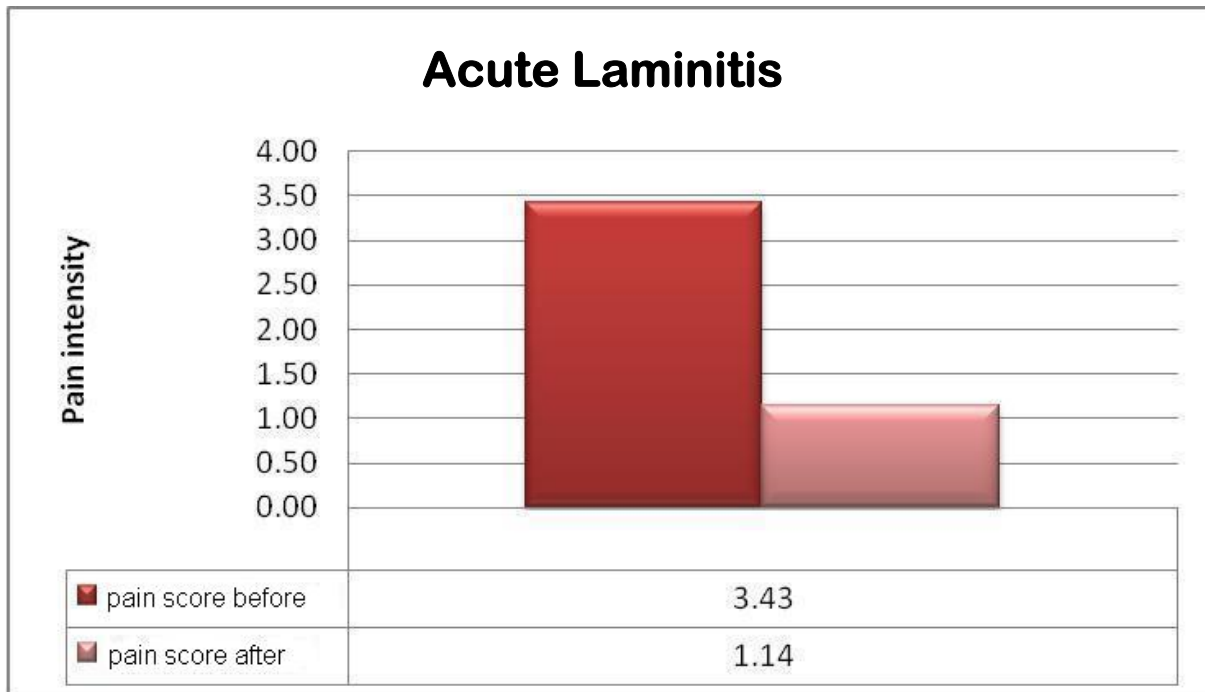


Figure 10: Comparison of pain scores before and after low level impulse laser acupuncture with or without topical wound treatment in fourteen horses with acute laminitis (mean and standard deviation of pre-treatment pain scores = 3.43 ± 1.02 and post-treatment pain scores 1.14 ± 0.36 , t-test= $p < 0.001$)

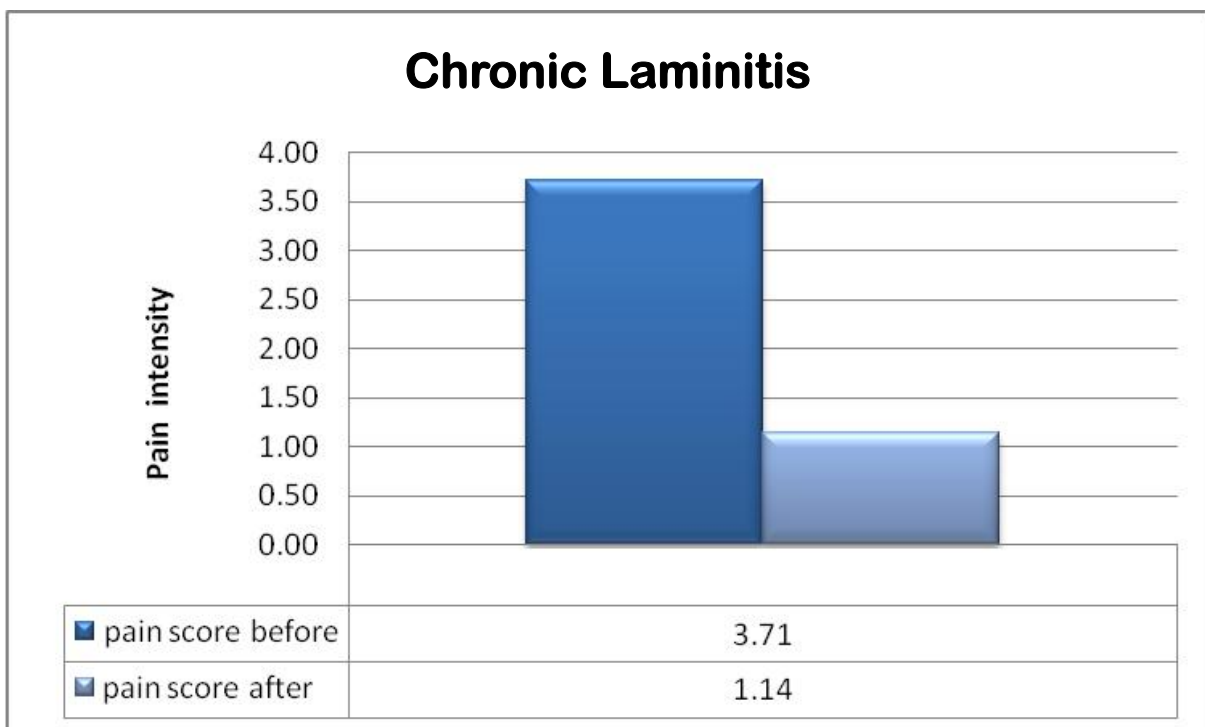


Figure 11: Comparison of pain scores before and after low level impulse laser acupuncture with or without topical wound treatment in seven horses with chronic laminitis; the mean and standard deviation of pre-treatment pain scores were 3.71 ± 0.76 and post-treatment pain scores 1.14 ± 0.38 , t test= $p < 0.001$